



## PATIENT

Smokey Bridges

## SPECIES

Feline

## BREED

DSH

## SEX

Male Neutered

## AGE

2.7 years

## WEIGHT

16.2lbs

## INTERPRETED BY

Maggie Machen Lamy,  
DVM, DACVIM  
(Cardiology)

## IMAGING PERFORMED BY

Hesham Akbawy, DVM

## HOSPITAL NAME

Lincoln Avenue Cat  
and Dog Hospital

## REFERRING VET

Dr. Akbawy

## INVOICE

45931

## DATE

12/1/25

## PRESENTING CLINICAL SIGNS

History: Grade 2/6 heart murmur. Elevated BNP: 800. BP: 159mmHg.

## ECHOCARDIOGRAM FINDINGS

2D, m-mode, color flow and doppler imaging is available. The left ventricular wall is normal in dimension. There is a mildly hyperechoic endocardium. The papillary muscles appear mildly remodeled. The left atrium is normal in size. The MV is normal in appearance with no systolic anterior motion seen. No significant MR. Blood flow through the LVOT appears normal with no evidence of obstruction. The right atrium is normal in size. The right ventricle appears normal. The tricuspid valve appears normal in structure and mobility. Trace tricuspid regurgitation. Blood flow through the RVOT is mildly elevated in velocity, likely secondary to tachycardia creating a benign outflow tract obstruction. No evidence of cardiac tumors or metastatic lesions on this scan.

## CARDIAC CHART

FELINE CARDIAC PARAMETERS	BODY WEIGHT (kg)	HR (BPM)	IVSd (cm) <small>(Moise, Pipers)</small>	LVIDd (cm) <small>(Moise, Pipers)</small>	LVWd (cm) <small>(Moise, Pipers)</small>	FS (%)	EF (%)
NORMAL PARAMETER	-----	150-240	0.35-0.55	<2 (mean 1.5)	3.5-0.55	35-67	80-100
PATIENT	7.3	NM	0.40	1.6	0.42	47	90
FELINE CARDIAC PARAMETERS	LA/AO <small>(Boon)</small>	LA/AO HEART BASE (Swe) <small>(Abbott)</small>	LA 2D short axis Base view (cm) <small>(Abbott)</small>		LVOT VEL <small>(m/s)</small>	RVOT VEL <small>(m/s)</small>	E max <small>(m/s)</small>
NORMAL	<1.5	<1.3	<1.2		<1.6	<1.3	<0.9
PATIENT	NM	1.4	1.3		1.0	>1.5	NM

*\*Note: All measurements based upon multi-modal images and methods. An average value is reported.  
Adapted from June Boon, Veterinary Echocardiography, 1998  
Abbott J & MacLean H JVIM 2006;20: 111-119, Moise et al. Am J Vet Res 47:1476, 1986. Pipers et al. Am J Vet Res 40:882, 1979.*

## INTERPRETATION OF THE FINDINGS & FURTHER RECOMMENDATIONS

The only cause of a murmur identified is a heart rate dependent flow obstruction through the right ventricle (DRVOTO), which is a physiologic finding (i.e., benign and of little clinical significance). This type of flow murmur will wax and wane secondary to tachycardia and volume changes. There is mild LV remodeling and fibrosis, which is likely a normal age-related finding. Regardless, the left atrial dimension is normal, and there is minimal risk for complication at this time. No additional abnormalities are seen.

These findings would likely suggest that BNP elevation in this young, otherwise healthy cat is likely a false positive result (a known weakness of the test). Utility lifelong will be limited.

Given these findings, no medications are indicated at this time. Prognosis is good, without significant pathology seen.

If needed, the risk for general anesthesia is low.



## PATIENT

Smokey Bridges

## SPECIES

Feline

## BREED

DSH

## SEX

Male Neutered

## AGE

2.7 years

## WEIGHT

16.2lbs

## INTERPRETED BY

Maggie Machen Lamy,  
DVM, DACVIM  
(Cardiology)

## IMAGING PERFORMED BY

Hesham Akbawy, DVM

## HOSPITAL NAME

Lincoln Avenue Cat  
and Dog Hospital

## REFERRING VET

Dr. Akbawy

## INVOICE

45931

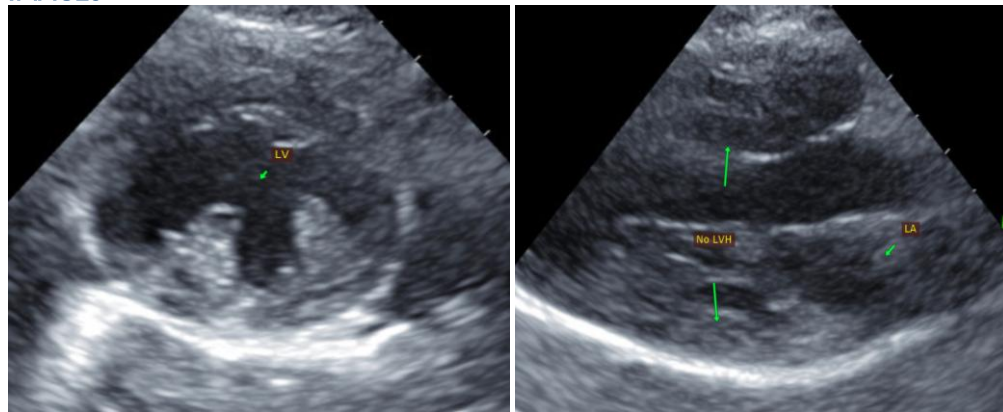
## DATE

12/1/25

Risk for complication with steroid use typically follows LA dilation, which in this case is low. That being said, any cat can experience unexpected signs of intolerance and monitoring of RR/RE is advised particularly in the initiation phase.

Recommend recheck echocardiogram in 1 year to assess for progression or development of disease the pre-existing murmur may mask.

## IMAGES



The information and recommendations provided are based on the images presented by the referring veterinarian. No evaluation can be communicated regarding pathology that was not visible in the image/video clips provided.

Thank you for this referral. This report was generated using transcription software, and minor dictation errors may be present. If the clinical or image interpretation does not parallel your findings or if I can be of any further assistance, please contact me.

Maggie Machen Lamy, DVM  
Diplomate of the American College of Veterinary Internal Medicine (Cardiology)  
info@sonopath.com